



## HALLUX RIGIDUS:

Maximizing Range of Motion through Implant Design, Intra- and Postoperative Management

**Carl Hasselman, MD**

University of Pittsburgh Medical Center  
Pittsburgh, PA

**Brian Carpenter, DPM**

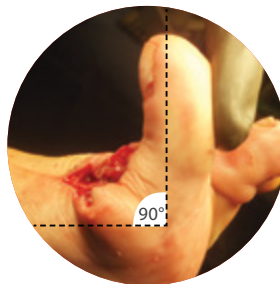
University of North Texas  
Health Science Center,  
Fort Worth, TX

### Intraoperative Management:

- Soft Tissue Mobilization
  - Capsular release
  - Collateral ligament mobilization
  - Sesamoids mobilization
- Joint Decompression:
  - Advance screw by 2-3 mm
  - Re-ream implant bed and reshape metatarsal head
- Flexor Hallucis Brevis Tendon Release
  - Subperiosteal release at the bony insertion on the proximal phalanx

### Intraoperative Goal:

- 90 degrees of passive dorsiflexion



### Postoperative Management:

- Patients are instructed in passive and active dorsi- and plantar-flexion preoperatively, and these instructions are repeated immediately postoperatively.
- Heel to toe gait and no walking on the side of the foot are encouraged.
- Patients without adjunct procedures are weight bearing immediately in a surgical boot or stiff-soled shoe for comfort and outside ambulation, but full weight bearing without a shoe in the household is encouraged immediately to prevent joint stiffness.
- Aggressive ROM therapy is initiated after healing of the integument.
- Return to normal shoe gear and activities after suture removal as tolerated.
- Early joint mobilization has not interfered with normal wound healing.
- No postoperative bracing is used to maintain alignment. No postoperative deformities have been seen by the authors.



### Arthrosurface HemiCAP<sup>DF</sup>® Toe Resurfacing System:

Joint Decompression and improved DorsiFlexion through anatomic non-spherical implant design re-establishing multiple anatomic centers of rotation over the full range of motion arc.

### References:

- 1) Hasselman C, Shields N. Resurfacing of the First Metatarsal Head in the Treatment of Hallux Rigidus. Tech in Foot & Ankle Surgery 7(1):31-40, 2008
- 2) Carpenter B, Smith J, Motley T, Garrett A. Surgical Treatment of Hallux Rigidus Using a Metatarsal Head Resurfacing Implant: Mid-term Follow-up. J Foot Ankle Surg. 2010 July - August;49(4):321-325.
- 3) Kinematics of the First Metatarsophalangeal Joint. MJ Shereff, FJ Bejjani, FJ Kummer. JBJS: Vol 68-A, No 3, 1986

